

Veterinary Apitherapy

A Collaborative Case Study

Glenn Perry
GlenHeaven Propolis
Branford, CT

www.wholepropolis.com

Ina Abercrombie
Dancing Bee Acres
Irrigon, OR

www.dancingbeeacres.com



8/27/06

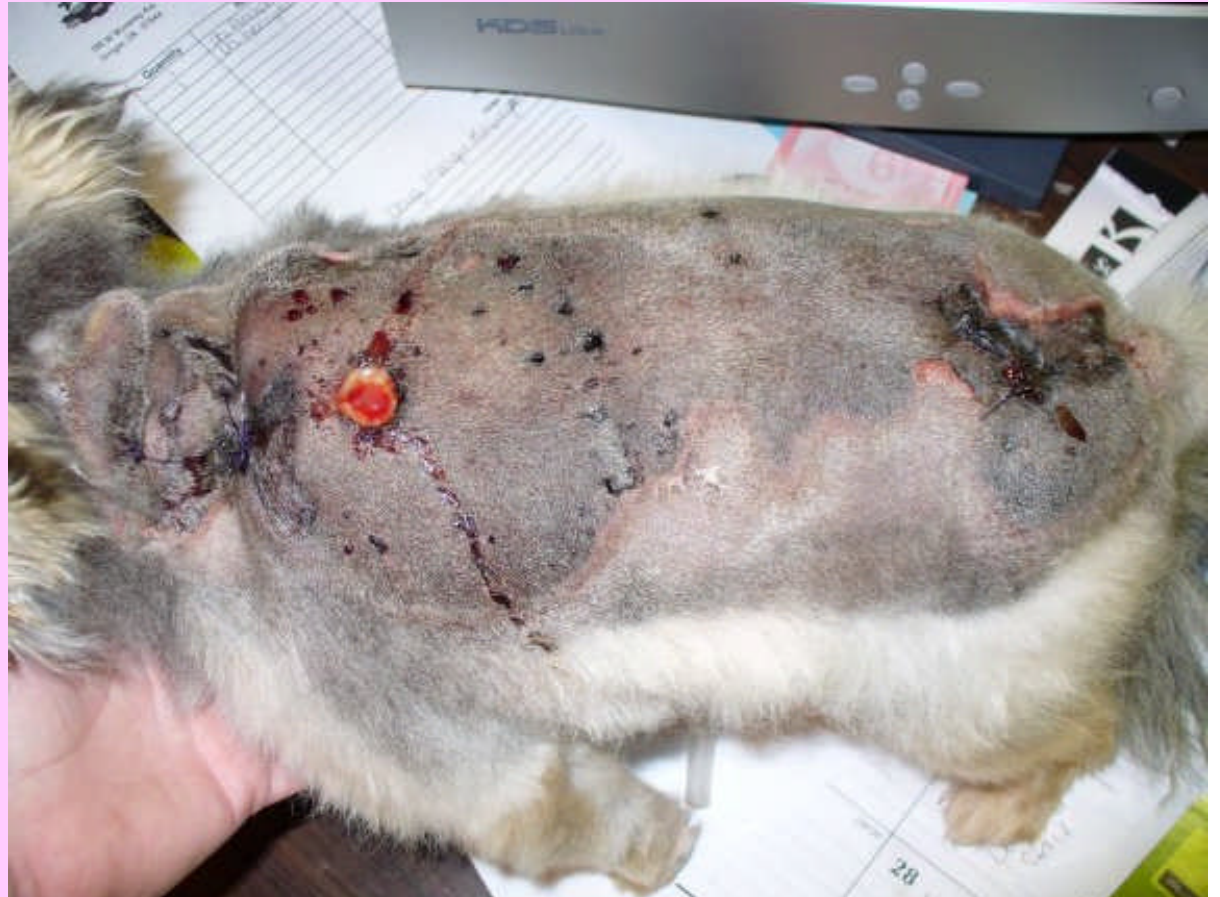Injury caused by a large dog attack of smaller dog.
Multiple puncture wounds across back.
Skin torn open at rump and shoulder.
Separation of the skin to the under lying tissue with
edema buildup with tendency to split and drain.
Skin on back seems to be dying.

Treatment Prior to
Apitherapy-

Suturing skin tears.
Amoxicillin antibiotic.

Salix for water retention.
Betadine bath 2 times
daily.

Surgical redressing of
infected puncture wound.



Apitherapy Treatment

Goals while restoring health of animal –

- Prevention of Destructive Infections.
- Stimulate Regeneration of Underlying Tissues
- Preserve Dead Underlying Tissue to Protect Deep Wounds While Healing
- Stimulate Healing of Surface Wounds

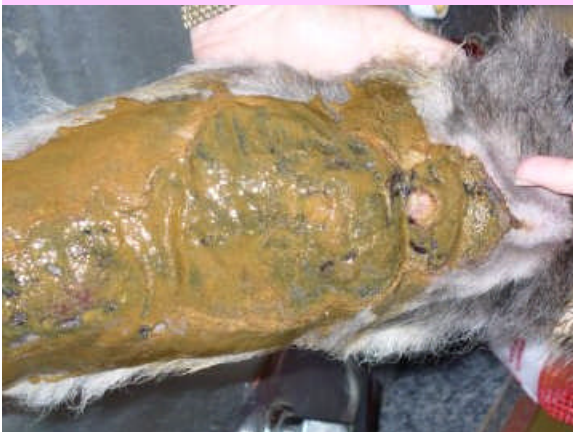Apitherapy Treatment Plan

Basic Treatment

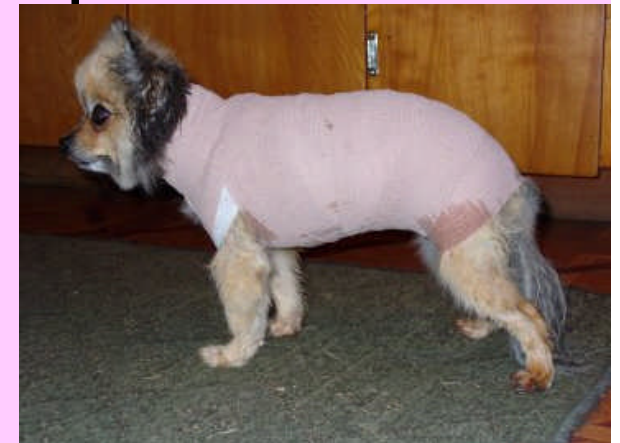Application of Mixture of 75% Honey + 25% Proprietary Solution of Whole Propolis in Water Covered by Dressing.

Clean Wounds and Reapply Every 5 – 7 Days.

Daily oral dosage of Honey & Propolis.



The heavy propolis percentage 'mummified' the necrotic tissues, allowing longer periods between re-applications.

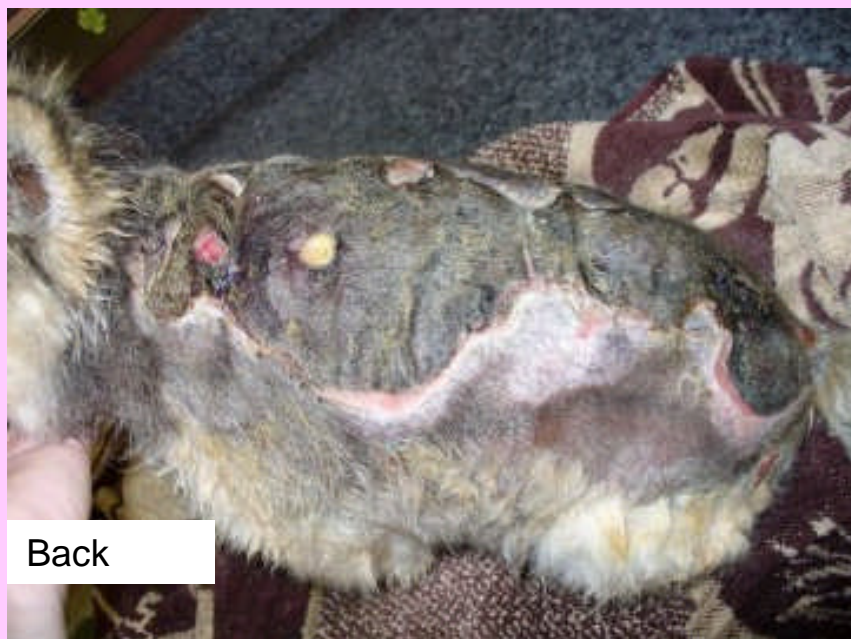

The Dressing Was Changed 2 Days After 1st Treatment.

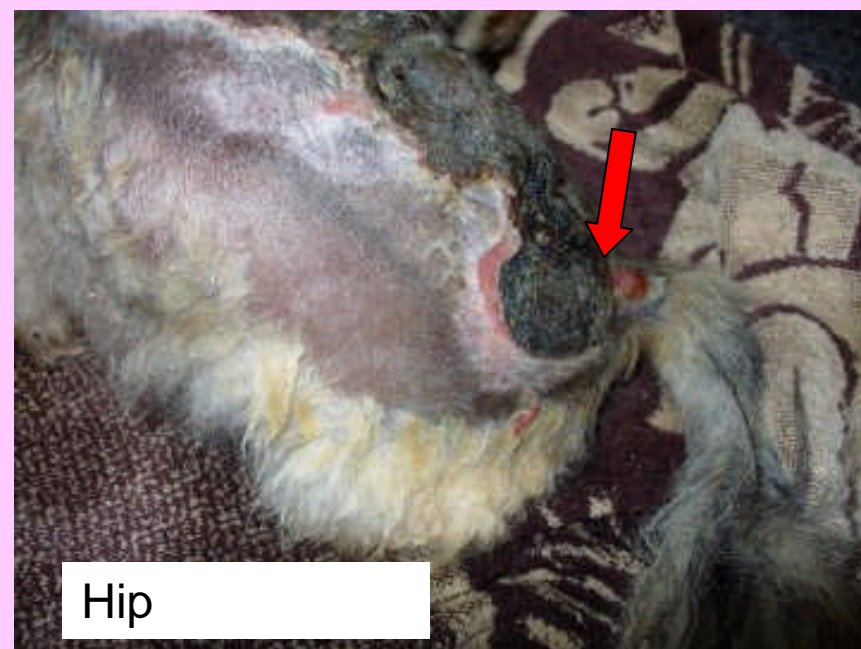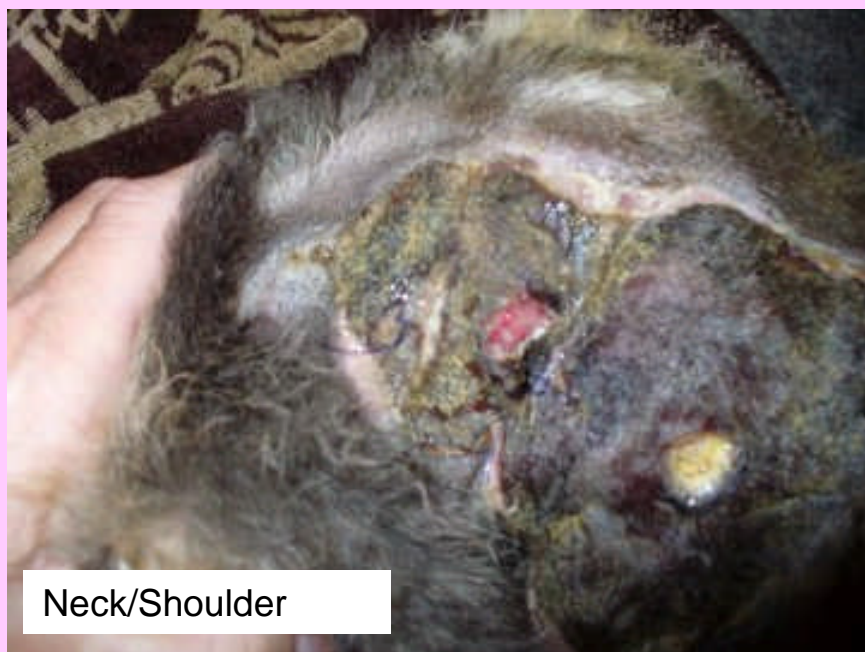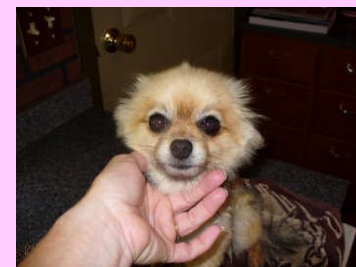


“I think it actually looked a little better ...the tightness [edema] wasn't so firm and there was some oozing from the open wounds, which I took to be good.”

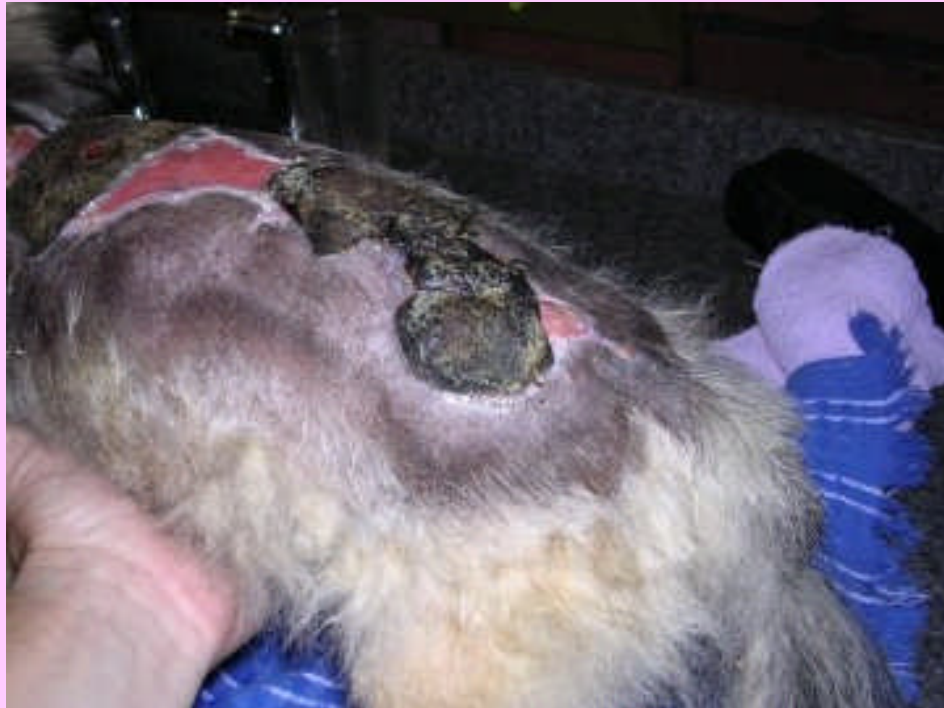- Ina A.



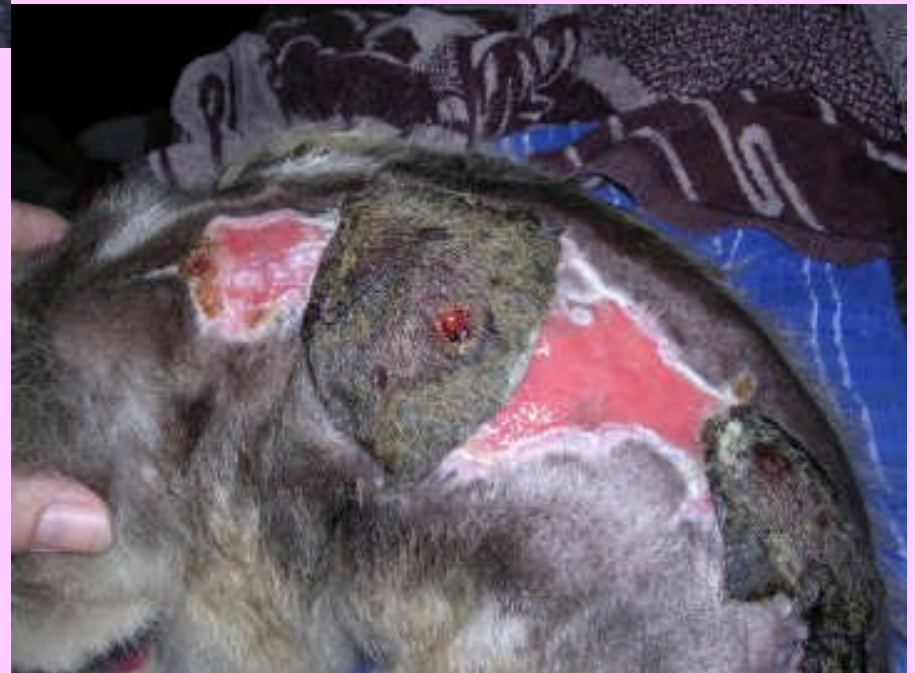Dressing again removed on 4th day of treatment due to “putrid” smell. Sutured wound on left hip had broken open and was draining. This was regarded as positive.



9/13/06



Ah...Isn't she sweet.?
She hates to get her
little front feet wet.

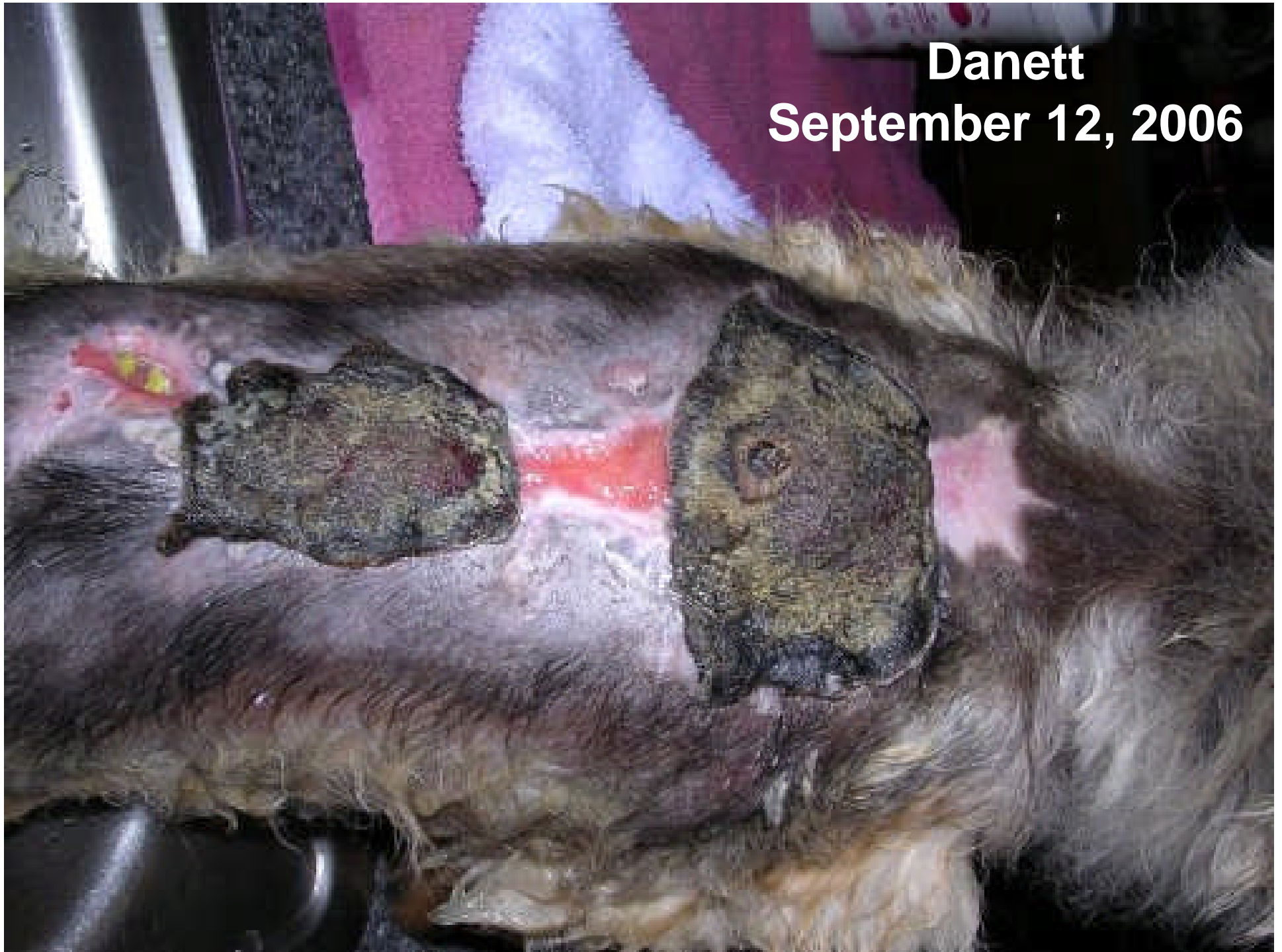

Danett
September 12
2006

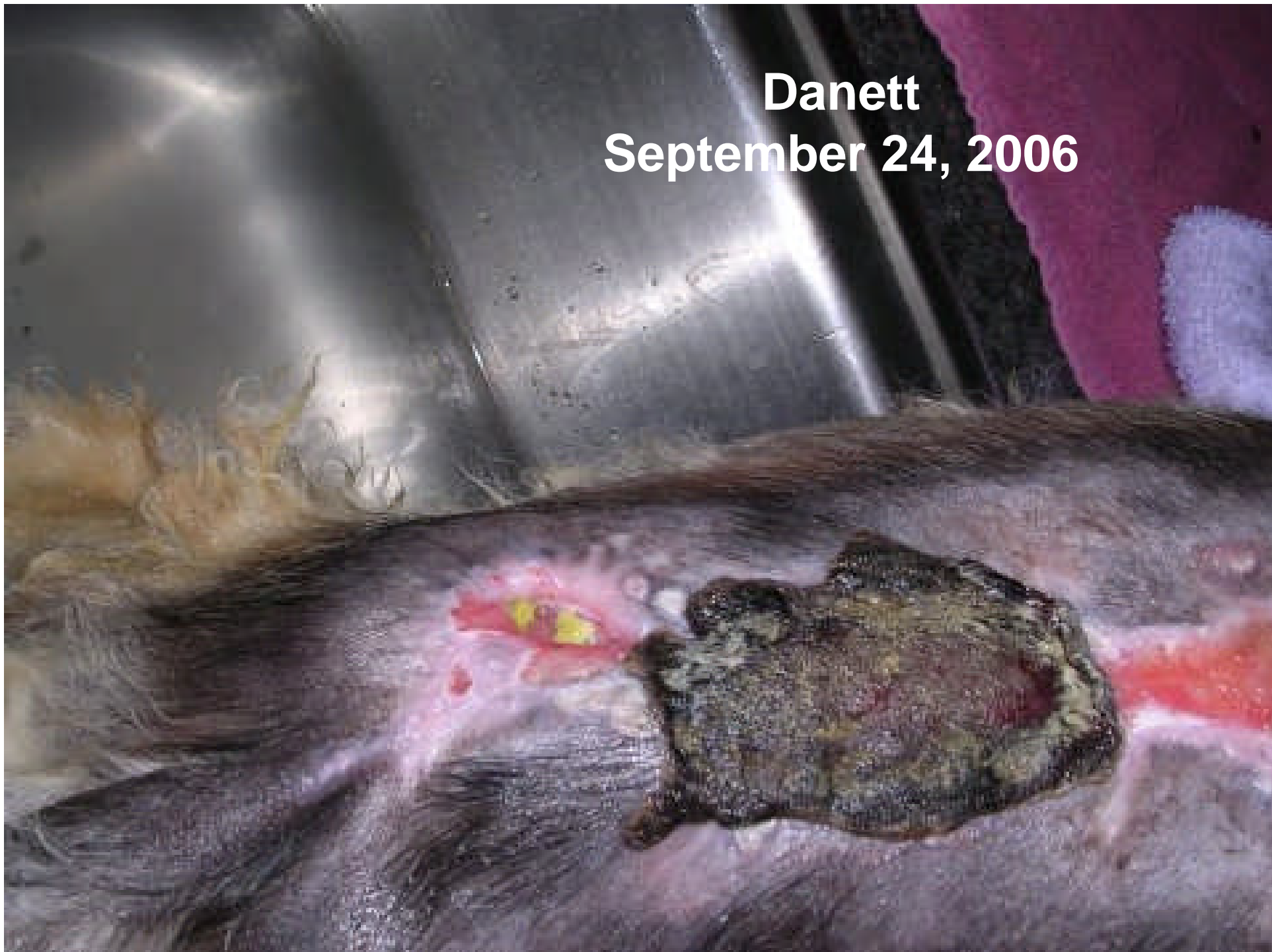2 Weeks Into Treatment.

Dead tissue is lifted to be trimmed as new
tissue develops.

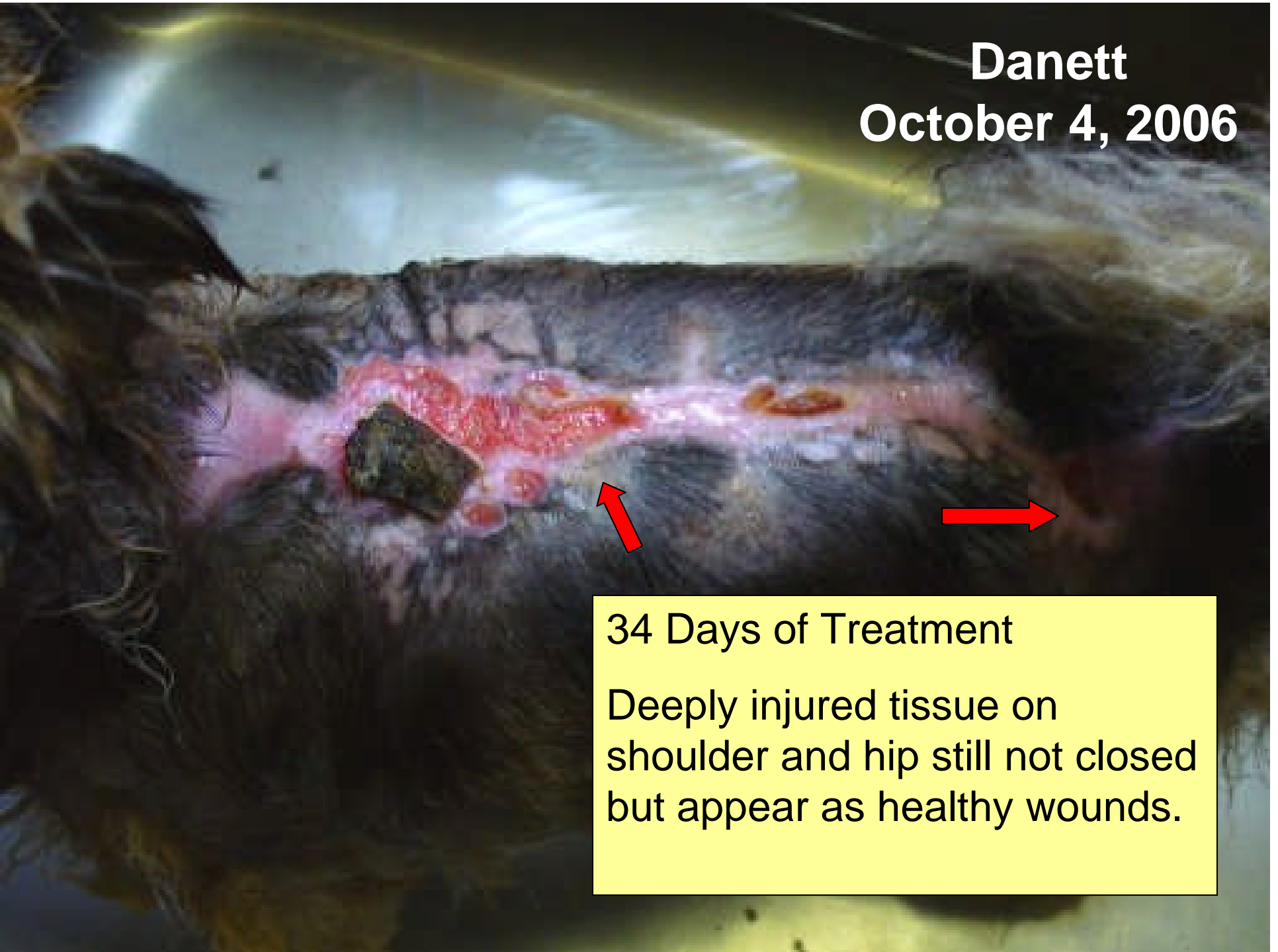
Danett
September 12, 2006



Danett
September 24, 2006



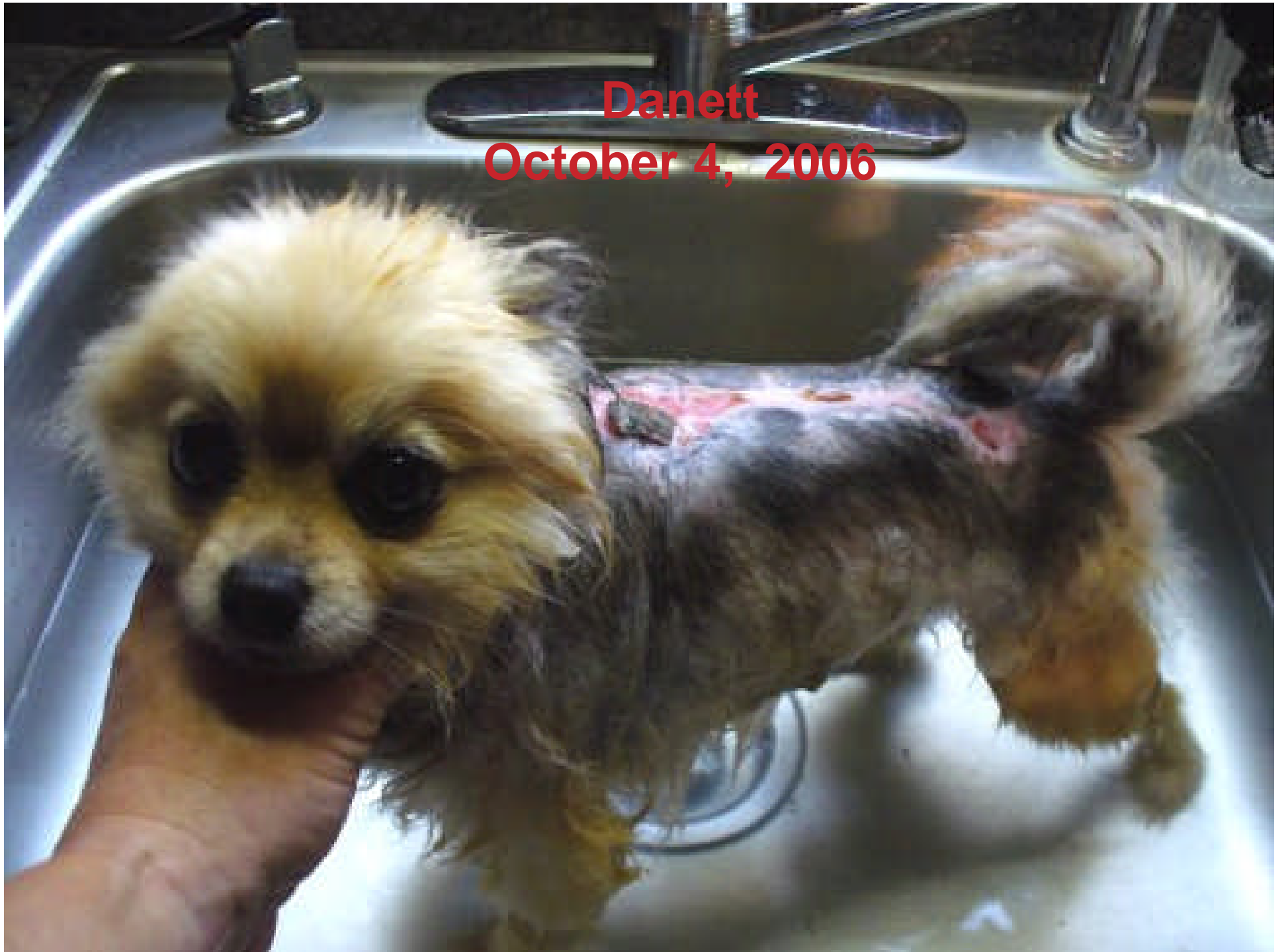Danett
October 4, 2006



34 Days of Treatment

Deeply injured tissue on
shoulder and hip still not closed
but appear as healthy wounds.

Danett
October 4, 2006



October 14, 2006

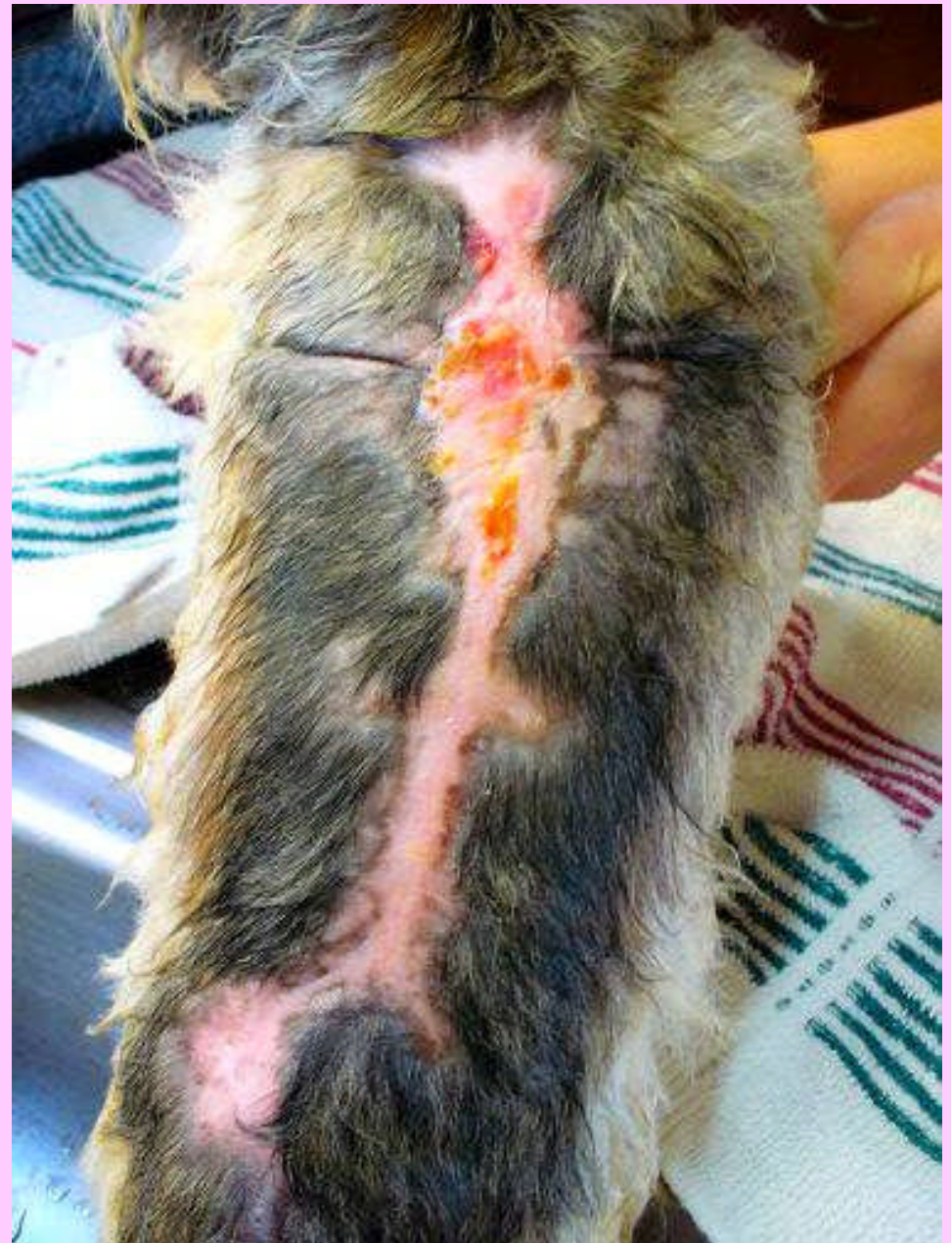Final closure of deepest wounds almost accomplished.

Conclusions

Digital photography, email, and telephone made this collaboration possible.

A private veterinary case provided an opportunity to treat a serious condition thereby gaining experience and confidence.

Honey and propolis were easy to work with and accomplished our treatment goals most effectively.





Danett
April 24, 2007

Epilogue

The healing was complete.

Hair regrew in some areas.